

FINAL ANSWER KEY

Question Paper Code:	86/2026/OL
Category Code:	685/2025
Exam:	Assistant Professor in Cardio Vascular and Thoracic Surgery
Date of Test	09-05-2026
Department	Medical Education

Question1:-The terminal groove on the right atrium externally corresponds internally with the

A:-crista terminalis

B:-left venous valve remnant

C:-sinus venosus

D:-Bachman's bundle

Correct Answer:- Option-A

Question2:-The following are true of single atrial cannulation except

A:-simpler and faster

B:-interferes least with venous return when off bypass

C:-drainage is less sensitive to heart positioning

D:-less traumatic

Correct Answer:- Option-C

Question3:-Hypothermia exerts its protective effects by all except

A:-reduction in metabolic rate and oxygen consumption

B:-reduction in high energy phosphate stores

C:-reducing excitatory neurotransmitter release

D:-reducing calcium entry into cells

Correct Answer:- Option-B

Question4:-The action of mannitol in cardioplegia is to

- A:-buffer acidosis
- B:-stabilise membrane potential and reduce arrhythmias
- C:-arrest the heart
- D:-scavenge oxygen radicals

Correct Answer:- Option-D

Question5:-All of the following are features of low cardiac output after cardiac surgery except

- A:-wide pulse pressure
- B:-blunted or dampened upstroke on arterial waveform
- C:-increased anion gap
- D:-pleural effusion

Correct Answer:- Option-A

Question6:-Rivaroxaban is an oral direct factor Xa inhibitor used for all except

- A:-thromboembolism prophylaxis
- B:-DVT treatment
- C:-Valvular atrial fibrillation
- D:-pulmonary embolism

Correct Answer:- Option-C

Question7:-Which of the following is associated with lower stroke rates?

- A:-avoiding use of intraoperative carbon dioxide
- B:-keeping starting haematocrit below 25
- C:-limiting rewarming to 35°C
- D:-avoiding y and t grafts

Correct Answer:- Option-C

Question8:-Bio membrane mimicry uses a coating of

A:-heparin

B:-phosphorylcholine derivative

C:-polyethylene oxide

D:-methoxyethyl acrylate

Correct Answer:- Option-B

Question9:-VAC therapy for deep sternal wound infection uses a pressure of

A:-0 to 25 mm Hg

B:-25 to 75 mm Hg

C:-75 to 125 mm Hg

D:-125 to 205 mm Hg

Correct Answer:- Option-C

Question10:-Which of the following will not reduce incidence of ventilator associated pneumonia?

A:-Avoiding head end elevation

B:-Sedation vacations

C:-peptic ulcer prophylaxis

D:-DVT prophylaxis

Correct Answer:- Option-A

Question11:-True statement about right ventricular infarction (RVI) include all of the following EXCEPT

A:-RVI may be accompanied by Kussmaul's sign

B:-ST segment elevation in lead V4 is commonly present in RVI

C:-Echocardiography may help distinguish RVI from pericardial effusion and cardiac tamponade

D:-Sequential atrioventricular pacing may be of benefit in selected patient with RVI

Correct Answer:- Option-B

Question12:-A 60-year-old man comes to the coronary care unit with severe chest pain. His ECG reveals 2 mm ST segment elevations in leads II, III and AVf. The initial cardiac

examination is unremarkable. On the second day a faint late systolic murmur is heard and by third day this murmur has increased to grade 3/6. The patient has mild dyspnoea, and a chest film shows pulmonary vascular redistribution. The most likely explanation of the murmur is:

A:-Ruptured posterior papillary muscle

B:-Ruptured anterior papillary muscle

C:-Infarcted posterior papillary muscle

D:-Infarcted anterior papillary muscle

Correct Answer:- Option-C

Question13:-LV aneurysm may develop as a consequence of acute MI. True statement about LV aneurysm EXCEPT

A:-LV aneurysm complicating acute MI is usually due to total occlusion of the Left anterior descending artery

B:-Inferoposterior aneurysms are slightly more common than apical aneurysms

C:-Persistent ST- segment elevation in an ECG area of infarction indicates a large infarct but does not necessarily indicate an aneurysm

D:-Aneurysm usually range in size from 1 to 8 cm in diameter

Correct Answer:- Option-B

Question14:-The following patients are best treated with coronary artery bypass grafting (CABG)

A:-A 60-year-old man with class II angina, 75percent proximal right coronary artery lesion, and normal ventricular function

B:-A 60-year-old man with dyspnea with class III, triple vessel diffuse disease with LV ejection fraction 20-30 percent

C:-A 60-year-old man with unstable angina, diabetic, triple vessel disease and an ejection fraction 35 percent

D:-A 60 year-old-man without diabetes with class III angina symptoms and discrete lesion in mid right coronary artery and mid left circumflex artery

Correct Answer:- Option-C

Question15:-Perioperative myocardial infarction occurs following coronary bypass procedure in approximately;

A:-15 percent

B:-10 percent

C:-7 percent

D:-less than 5 percent

Correct Answer:- Option-D

Question16:-Which of the following statements about patients treated by placement of an internal mammary artery (IMA) bypass graft at primary CABG is incorrect?

A:-Left ventricular function is better preserved at the time of reoperation

B:-The risk of sternal wound complications is greatly increased if the contralateral IMA is harvested at the time of reoperation

C:-A light clamps should be applied to the IMA pedicle to limit cardiac warming during cardioplegic arrest at the time of reoperation

D:-A functional study demonstrating a large portion of myocardium at risk should be obtained before reoperation

Correct Answer:- Option-B

Question17:-Following acute myocardial infarction, ventricular septal defects occur in:

A:-20%

B:-10%

C:-15%

D:-2% or less

Correct Answer:- Option-D

Question18:-Which statement about operative mortality and perioperative incidence of myocardial infarction for elective CABG (X) versus emergency CABG following failed PTCA (Y) is accurate?

A:-The operative mortality is higher for Y but the incidence of perioperative myocardial infarction is unchanged between X and Y

B:-The operative mortality is unchanged between X and Y but the perioperative incidence of myocardial infarction is higher in Y

C:-The operative mortality and perioperative incidence is higher in X than in Y

D:-The operative mortality and perioperative incidence of myocardial infarction are no different for X and for Y

Correct Answer:- Option-C

Question19:-If blood entering the normal arterial circulation of the heart is 100% saturated with oxygen, oxygen saturation of blood in the coronary sinus can be expected to be approximately:

A:-Less than 20%

B:-60%

C:-50%

D:-35%

Correct Answer:- Option-D

Question20:-Which of the following statements about collaterals in the normal coronary circulation is true?

A:-There is a rich and quite effective collateral circulation in the coronary arterial bed

B:-The coronary arterial bed has minimal effective collaterals

C:-The coronary arterial bed is an absolute example of anatomic end-arteries

D:-The magnitude of collateral are fixed in coronary bed

Correct Answer:- Option-B

Question21:-What is the average life expectancy; once a patient develops cardiac failure in Aortic Stenosis?

A:-5 years

B:-3.5 years

C:-1.5 years

D:-6 years

Correct Answer:- Option-C

Question22:-Which of the following statements is/are correct regarding functional anatomy of mitral, aortic and tricuspid valves?

i. Type III a dysfunction in mitral regurgitation (Carpentier classification) describes restricted leaflet motion in systole only.

ii. Sino tubular junction is the narrowest part of the aortic root.

iii. Tricuspid valve annulus is saddle shaped and non planar

iv. The area corresponding to the anteroseptal commissure of tricuspid valve is close to right coronary cusp (RCC) of aortic valve.

A:-Only (i & ii)

B:-Only (ii & iii)

C:-Only (i, ii & iii)

D:-All of the above

Correct Answer:- Option-B

Question23:-Indications for Ross procedure includes all EXCEPT

A:-Young active patients with aortic valve disease

B:-Woman Of child bearing age group with aortic valve disease

C:-Congenital aortic valve disease

D:-Connective tissue disorders affecting Aortic root

Correct Answer:- Option-D

Question24:-With reference to Systolic Anterior Motion (SAM) in mitral valve repair, all statements are true EXCEPT.

A:-5-10 % incidence after mitral valve repair

B:-Common in patients with myxomatous degeneration

C:-Seen in patients with excessively hypertrophied left ventricle

D:-Substitution with small, rigid or full Annuloplasty ring is effective in managing SAM

Correct Answer:- Option-D

Question25:-In patients with Tricuspid Regurgitation secondary to Mitral valve disease, Tricuspid Annuloplasty is generally performed if Tricuspid annulus diameter is

A:-> 20 mm

B:-> 35 mm

C:-> 40 mm

D:-> 45 mm

Correct Answer:- Option-B

Question26:-Regarding Annulo aortic ectasia, all statements are true EXCEPT.

A:-Most often caused by Cystic Medial Degeneration

B:-Aortic cusps may be unaffected

C:-Dilation of aortic wall at Sino-tubular junction

D:-LV- aortic junction is also usually increased in size

Correct Answer:- Option-D

Question27:-Who has first reported simultaneous Aortic and Mitral valve replacement with mechanical prosthesis?

A:-Albert Starr and colleagues

B:-Lillehei and colleagues

C:-Cart Wright and colleagues

D:-Likoff and Colleagues

Correct Answer:- Option-C

Question28:-Choose the CORRECT statement /Statements about Mitral Regurgitation from Ischemic heart disease.

(i) Papillary muscle dysfunction is the most common cause for severe MR in acute MI

(ii) In patients with papillary muscle rupture; 75% of rupture occurs in Anterior papillary muscle.

(iii) Papillary muscle rupture occurs typically 2 to 7 days after acute infarction.

(iv) First successful surgical correction of papillary muscle rupture was reported by Austen and colleagues.

A:-Only (i & ii)

B:-Only (i, iii & iv)

C:-Only (iii)

D:-All of the above

Correct Answer:- Option-B

Question29:-Which is the most common etiologic organism in acute Tricuspid valve endocarditis?

A:-*Pseudomonas aeruginosa*

B:-*Staphylococcus aureus*

C:-*Candida albicans*

D:-*Streptococcus viridans*

Correct Answer:- Option-A

Question30:-Which is the most common congenital heart disease in adults?

A:-Atrial septal defects

B:-Ventricular septal defects

C:-Bicuspid Aortic valve

D:-Coarctation of Aorta

Correct Answer:- Option-C

Question31:-A patient on VVI pacing develops hypotension and syncope despite adequate rate. What is the mechanism by which VVI pacing can cause hypotension?

A:-Ventricular dyssynchrony

B:-Loss of AV dyssynchrony with atrial contraction against closed AV valve

C:-Reduced coronary perfusion

D:-Increased after load

Correct Answer:- Option-B

Question32:-Which condition predisposes to spontaneous complete heart block due to bundle elongation?

A:-Tetralogy of fallot

B:-AV discordance

C:-Atrial septal defect

D:-Ebstein's anomaly

Correct Answer:- Option-B

Question33:-Sinus node dysfunction after A.SO is mainly due to

A:-Direct node excision

B:-Increased Vagal tone

C:-Right atrial dilatation

D:-Ischemia from sinus nodal artery injury

Correct Answer:- Option-D

Question34:-A: Congenital complete heart block (CHB) may present despite normal anatomy

R : Progressive fibrosis of conduction pathways may develop over time

A:-Both A & R are true, R explains A

B:-Both A and R are true, R doesn't explain A

C:-A true R false

D:-A false R true

Correct Answer:- Option-B

Question35:-The most common cause of sudden death in complete heart block (CHB) is

A:-Ventricular fibrillation

B:-AV nodal reentry

C:-Atrial stand still

D:-Ventricular asystole

Correct Answer:- Option-D

Question36:-In cardiac tamponade due to trauma

A. Hypotension may be absent in early traumatic cardiac tamponade.

R. Rapid accumulation of pericardial blood limits compensatory pericardial stretch

A:-A true R false

B:-A false R true

C:-Both A and R are true, R doesn't explain A

D:-Both A and R are true, R explains A

Correct Answer:- Option-C

Question37:-A blunt trauma patient with persistent arrhythmias and elevated troponin but hemodynamically stable. Which is the best management strategy?

A:-Emergency cardiopulmonary bypass

B:-Pericardiotomy

C:-Observation with monitoring

D:-Immediate sternotomy

Correct Answer:- Option-C

Question38:-A 35 year old symptomatic patient with HOCM has,

- LVOT gradient of 80 mm of HG
- Severe septal hypertrophy
- Moderate MR due to systolic anterior motion (SAM) of mitral valve

Surgeon performs an adequate septal myectomy. However, intra operative TEE still shows significant LVOT gradient and MR.

What is the most appropriate next step?

A:-Increase depth of septal resection

B:-Replace mitral valve

C:-Address abnormal mitral sub valvular apparatus

D:-Initiate CPB weaning

Correct Answer:- Option-C

Question39:-Which maneuver MOST increases LVOT obstruction in HOCM (Hypertrophic obstructive cardiomyopathy)

A:-Squatting

B:-Hand grip

C:-Valsalva strain reflex

D:-Volume loading

Correct Answer:- Option-C

Question40:-In a post myectomy HOCM patient is hypotensive gradient shoots up and severe SAM on TEE. Inotropic support kept is 6 µg/kg/min of dobutamine what all things would you not do out of following four choices?

A:-Stop dobutamine start adrenaline

B:-Volume loading

C:-Start beta blocker

D:-Give phenylephrine

Correct Answer:- Option-A

Question41:-The hallmark hemodynamic feature of dilated cardiomyopathy is

A:-Reduced ventricular compliance

B:-Increased systolic function

C:-Reduced ejection fraction with ventricular dilatation

D:-Increased myocardial thickness

Correct Answer:- Option-C

Question42:-The classic ECG finding in Arrhythmogenic Right Ventricular Cardiomyopathy is

A:-Epsilon wave

B:-Delta wave

C:-ST elevation

D:-T wave inversion in V1 only

Correct Answer:- Option-A

Question43:-Hyper acute rejection is primarily mediated by

A:-T cells

B:-Preformed antibodies

C:-Macrophages

D:-Neutrophils

Correct Answer:- Option-B

Question44:-Acute cellular rejection is mainly mediated by

A:-B lymphocytes

B:-Platelets

C:-Complement system

D:-T lymphocytes

Correct Answer:- Option-D

Question45:-Harlequin syndrome in VA-ECMO refers to

A:-RV failure

B:-Upper body hypoxia due to mixing of flows

C:-Hemolysis

D:-Infection

Correct Answer:- Option-B

Question46:-Which of the following feature is characteristic of restrictive cardiomyopathy?

A:-Impaired ventricular filling with preserved systolic function

B:-Systolic dysfunction with dilation of all four chambers

C:-Asymmetric septal hypertrophy

D:-Right ventricular fibro-fatty replacement

Correct Answer:- Option-A

Question47:-The normal amount of pericardial fluid is

A:-0 - 5 mL

B:-10 - 50 mL

C:-100 - 200 mL

D:-> 200 mL

Correct Answer:- Option-B

Question48:-The characteristic ECG finding in acute pericarditis is

A:-ST depression

B:-Q wave

C:-T wave inversion only

D:-Diffuse ST elevation with PR depression

Correct Answer:- Option-D

Question49:-Beck's triad in cardiac tamponade includes

A:-Hypertension, bradycardia, edema

B:-Tachycardia, fever, chest pain

C:-Hypotension, jugular venous distension, muffled heart sounds

D:-Cyanosis, cough, wheeze

Correct Answer:- Option-C

Question50:-Kussmaul's sign refers to

A:-Decrease in JVP on inspiration

B:-Increase in JVP on inspiration

C:-Increase in JVP on expiration

D:-Decrease in systolic BP during inspiration

Correct Answer:- Option-B

Question51:-Which of the following statements are correct about acute aortic dissection?

(i) Hypertension is the major risk factor for acute aortic dissection

(ii) Type B aortic dissection requires urgent surgical intervention.

(iii) Intravenous beta-blockers are the first- line medical management in reducing aortic wall stress in acute aortic dissection.

(iv) Cobweb sign is used to identify the true lumen.

A:-Only (i & ii)

B:-Only (i & iii)

C:-Only (ii & iii)

D:-Only (i, iii & iv)

Correct Answer:- Option-B

Question52:-Which of the following statement about traumatic aortic disruption is false?

A:-the mechanism for traumatic aortic disruption is rapid acceleration/ deceleration

B:-The commonest site is aortic isthmus

C:-More than 8 cm widening of the mediastinum in X ray Chest is diagnostic of aortic disruption

D:-Thoracic endovascular aortic repair is the treatment in stable patients

Correct Answer:- Option-C

Question53:-Retrograde propagation of a Type A aortic dissection can lead to the following complications except:

A:-Myocardial ischemia and infarct

B:-Acute aortic regurgitation

C:-Stroke

D:-Pericardial tamponade

Correct Answer:- Option-C

Question54:-The type of Thoraco-abdominal aortic aneurysm that extends from left subclavian artery down to infra renal aorta as per Crawford classification is

A:-Extent I

B:-Extent II

C:-Extent III

D:-Extent IV

Correct Answer:- Option-B

Question55:-Which of the following statements about spinal cord protection is correct in Thoraco-abdominal aortic aneurysm surgery?

(i) Keep CSF fluid pressure above 15 cm of H₂O

(ii) temporary renal bypass helps to reduce paraplegia.

(iii) Maintaining adequate distal perfusion utilizing left atrio-femoral bypass is useful

(iv) Re-implantation of the lower uterocostal arteries are useful to prevent spinal schernia.

A:-Only (i, ii & iii)

B:-Only (ii & iv)

C:-Only (i, iii & iv)

D:-Only (iii & iv)

Correct Answer:- Option-D

Question56:-The primary pathological mechanism of a penetrating aortic ulcer is

A:-Ulceration of atherosclerotic plaque

B:-Tear in intimal layer

C:-Infective focus of the aortic wall

D:-Rupture of vasavatorum leading to intramural hematoma

Correct Answer:- Option-A

Question57:-A 45-year-old man with prior pulmonary embolism presents with progressive exertional dyspnea. Echo shows PA pressure of 40 mm Hg. CT pulmonary angiography is inconclusive. What is the best next step?

A:-Magnetic resonance pulmonary angiography

B:-Right heart catheterization

C:-Ventilation perfusion scan

D:-Start empirical anticoagulation

Correct Answer:- Option-C

Question58:-A 48-year-old lady presents with sudden onset of hypotension, tachycardia, and breathlessness, Echo shows McConnell's sign with RV dilatation. Patient is not stable enough to shift for a CT scan. The best management strategy will be:

A:-Start Heparin and Aspirin

B:-Insert IVC filter

C:-Start inotropes and supportive measures only

D:-Immediate systemic thrombolysis

Correct Answer:- Option-D

Question59:-Which haemodynamic profile is most consistent with massive pulmonary embolism?

A:-Hypotension, high PCWP

B:-Low cardiac output, high pulmonary vascular resistance

C:-Low SVR, Low PCWP and high cardiac output

D:-Hypotension, Low CVP and bradycardia

Correct Answer:- Option-B

Question60:-Which of the following radiological sign suggests pulmonary artery sarcoma?

A:-Wall eclipsing sign

B:-Air crescent sign

C:-Hampton Hump

D:-Westermarck sign

Correct Answer:- Option-A

Question61:-The Eustachian valve in the heart is related to

A:-Coronary sinus

B:-Superior Venacava

C:-Inferior Venacava

D:-PAPVC

Correct Answer:- Option-C

Question62:-Double aortic arch is due to failure of regression of

A:-Right sixth aortic arch

B:-Right fourth aortic arch

C:-Left sixth aortic arch

D:-All of the above

Correct Answer:- Option-B

Question63:-Ductal closure occurs in neonates due to

A:-Loss of placental source of prostaglandins

B:-Increased arterial oxygen tension

C:-Both 1 & 2

D:-Neither 1 nor 2

Correct Answer:- Option-C

Question64:-In Sinus venosus ASD,Warden Procedure consists of

A:-Baffling of PAPVC

B:-SVC anastomosis to Right atrial appendage

C:-Transection of SVC

D:-All of the above

Correct Answer:- Option-D

Question65:-The pathophysiology of isolated Cor Triatriatum sinistrum is similar to

A:-Tricuspid valve disease

B:-Mitral valve disease

C:-Aortic valve disease

D:-Pulmonary valve disease

Correct Answer:- Option-B

Question66:-The success of Fontan operation is NOT related to

A:- Low pulmonary vascular resistance

B:-Good pulmonary artery architecture

C:-Left Ventricular hypertrophy

D:-All of the above

Correct Answer:- Option-C

Question67:-In Carpentier's classification of Mitral regurgitation, mitral leaflet motion is enhanced in

A:-Type 1

B:-Type 2

C:-Type 3a

D:-Type 3b

Correct Answer:- Option-B

Question68:-DiGeorge syndrome includes

A:-Thymic hypoplasia

B:-Parathyroid deficiency

C:-Conotruncal cardiac anomaly

D:-All of the above

Correct Answer:- Option-D

Question69:-Regarding PH stat strategy,which is NOT true

A:-CO₂ is added to the circuit

B:-PH stat increases the Cerebral blood flow

C:-Microemboli more in PH stat

D:-In infants and children,Alfa stat strategy is preferred

Correct Answer:- Option-D

Question70:- Myocardial infarction in children is caused by

A:-Kawasaky disease

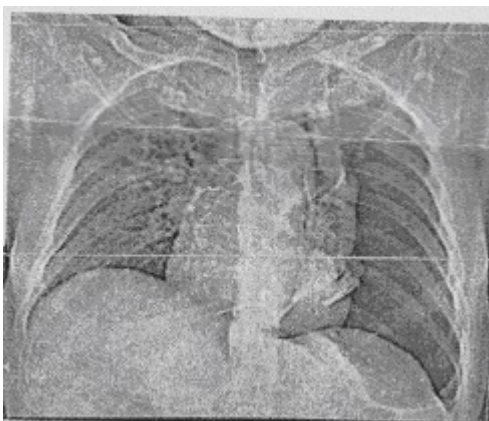
B:-ALCAPA

C:-Takayasu arteritis

D:-All of the above

Correct Answer:- Option-D

Question71:-A 45-year-old man undergoes ascending aorta replacement and is discharged uneventfully 2 weeks after surgery. The patient visits the follow-up OPD after 1 month and complains of progressive breathlessness for 2 days. Prior to breathlessness, there is a history of vigorous coughing due to an upper respiratory viral infection. The HRCT chest shows left sided pneumothorax.



What is the next best step in the management of this patient?

A:-Intercostal drainage tube followed by VATS in case of prolonged pleural air leaks

B:-VATS only

C:-Intercostal drainage tube placement followed by Pleurodesis

D:-VATS and pleurodesis in case of recurrent pneumothorax

Correct Answer:- Option-A

Question72:-All of the following findings in various investigations indicate a descending thoracic aortic injury EXCEPT

A:-Widened mediastinum and indistinct aortic knuckle on chest x-ray AP view.

B:-Periaortic hematoma on CT chest

C:-Pseudoaneurysm on DSA of the aorta

D:-Loss of imaging in the distal aortic arch on TEE

Correct Answer:- Option-D

Question73:-Which structure is located in the anterior mediastinum?

A:-Oesophagus

B:-Thymus

C:-Heart

D:-Ascending Aorta

Correct Answer:- Option-B

Question74:-All of the following muscles are involved in expiration EXCEPT

A:-External intercostals

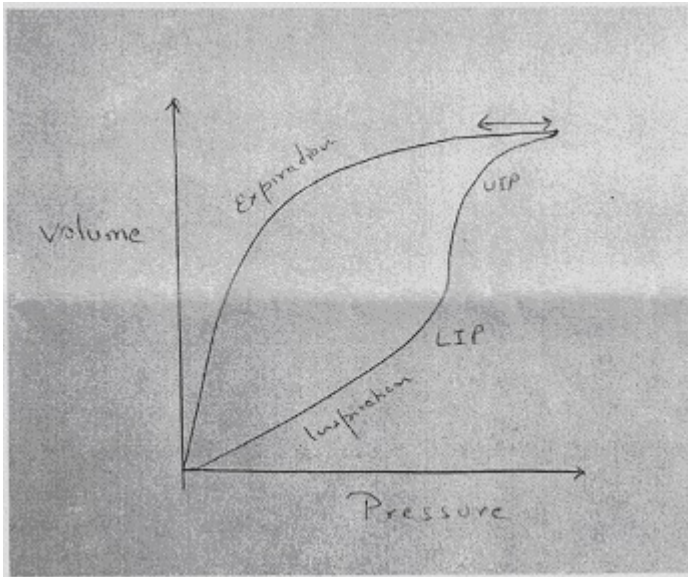
B:-Internal intercostals

C:- Rectus abdominis

D:-Transversus abdominis

Correct Answer:- Option-A

Question75:-Below is the image of a hysteresis loop during mechanical ventilation. What does the arrow denote?



- A:-Overdistension of alveoli
 - B:-Air leak
 - C:-Broncho pleural fistula
 - D:-Inadequate inspiratory flow
- Correct Answer:- Option-A

Question76:-Preterm neonates often develop respiratory insufficiency due to a lack of pulmonary surfactant. This surfactant is primarily made up of

- A:-Cholesterol
 - B:-Albumin
 - C:-Globulin
 - D:-Dipalmitoylphosphatidylcholine
- Correct Answer:- Option-D

Question77:-A 26-year-old male develops chylothorax after cardiac surgery. Which of the following criteria can be used to confirm the diagnosis?

- A:-Triglyceride levels > 110 mg/dL
 - B:-VLDL levels > 110 mg/dL
 - C:-Cholesterol levels > 110 mg/dL
 - D:-Chylomicron levels > 110 mg/dL
- Correct Answer:- Option-A

Question78:-A 28-year-old, postpartum female develops respiratory distress, hypotension and hypoxia, and is put on mechanical ventilation 24 h after delivery. Which of the following investigations may help in the diagnosis of pulmonary embolism in this patient?

A:-CRP

B:-ESR

C:-IL 6 levels

D:-D dimer levels

Correct Answer:- Option-D

Question79:-Delivery of oxygen is calculated as

$$DO_2 = [(1.34 \times [Hb] \times SaO_2) + (PaO_2 \times 0.0031)] \times \text{cardiac output}$$

The numerical 0.0031 is the solubility coefficient of oxygen in the blood. Its unit is

A:-mL O₂/dL/ mm Hg

B:-ml O₂/ mm Hg

C:-dL/mm Hg

D:-mL O₂/dL

Correct Answer:- Option-A

Question80:-A 6-year-old child develops right diaphragmatic palsy after corrective cardiac surgery. Which of the following nerves must have been injured?

A:-Right Phrenic nerve

B:-Dorsal Scapular nerve

C:-Vagus nerve

D:-Sympathetic plexus

Correct Answer:- Option-A

Question81:-A patient with a history of severe retching and vomiting suddenly develops acute chest pain, dyspnea and subcutaneous emphysema. What is the most likely diagnosis?

A:-Tension pneumothorax

B:-Aortic dissection

C:-Esophageal rupture

D:-Pneumonia with rupture of subpleural bleb

Correct Answer:- Option-C

Question82:-In delayed presentation (>24 hours) of spontaneous esophageal perforation with contained leak and minimal *sepsis*, which is the preferred management strategy?

A:-Primary surgical repair with wide drainage

B:-Esophagectomy with cervical diversion

C:-Nonoperative management with NPO, antibiotics, and drainage

D:-Endoscopic clipping or stenting with nasogastric decompression

Correct Answer:- Option-D

Question83:-A 58-year-old chronic smoker presents with shoulder pain Horner's syndrome, and weakness of intrinsic hand muscles. Imaging reveals a superior sulcus tumor with vertebral body erosion but no distant metastases. Next best step?

A:-Chemoradiotherapy followed by surgery

B:-Surgery alone via posterolateral thoracotomy

C:-Palliative radiation

D:-Neoadjuvant chemotherapy only

Correct Answer:- Option-A

Question84:-A patient with post-intubation tracheal stenosis at 3 cm below vocal cords undergoes segmental resection, Intraoperatively, the tension across anastomosis is high despite neck flexion. What additional maneuver is Justified?

A:-Inferior tracheal release

B:-Hilar release via right thoracotomy

C:-Suprahyoid laryngeal release

D:-Cricoid resection with thyrotracheal anastomosis

Correct Answer:- Option-C

Question85:-A solitary pulmonary nodule is discovered incidentally on a chest CT scan in an asymptomatic 60-year-old former smoker. What is the most appropriate next step in management?

A:-Immediate surgical resection (VATS)

B:-Observation with a repeat CT in 5 years

C:-Positron Emission Tomography (PET) scan and/or biopsy

D:-Bronchodilators

Correct Answer:- Option-C

Question86:-Chronic lung allograft dysfunction (CLAD) most commonly presents as:

A:-Restrictive allograft syndrome

B:-Bronchiolitis obliterans syndrome

C:-Acute rejection

D:-Diffuse alveolar damage

Correct Answer:- Option-B

Question87:-Ex vivo lung perfusion (EVLP) primarily helps in:

A:-Reducing rejection

B:-Expanding donor pool

C:-Preventing infection

D:-improving ventilation

Correct Answer:- Option-B

Question88:-Which sign is specific for diaphragmatic rupture on CT thorax?

A:-Ground-glass opacity

B:-Collar sign

C:-Halo sign

D:-Air bronchogram

Correct Answer:- Option-B

Question89:-Which is the best diagnostic tool for mediastinal staging in lung cancer?

A:-CT

B:-PET

C:-EBUS-TBNA

D:-MRI

Correct Answer:- Option-C

Question90:-A 32-year-old male presents after a high-speed deceleration injury. He is hemodynamically stable. Chest CT angiography shows a focal outpouching at the aortic isthmus with surrounding mediastinal hematoma. No active extravasation is seen. What is the most appropriate management?

A:-Immediate open surgical repair

B:-Endovascular stent grafting (TEVAR)

C:-Conservative management with blood pressure control

D:-Emergency thoracotomy

Correct Answer:- Option-B

Question91:-Which of the following anatomical criteria is generally considered unsuitable for a standard infrarenal endovascular aneurysm repair (EVAR) using most commercially available off-the-shelf stent grafts?

A:-An infrarenal neck length of 18 mm

B:-A proximal neck angulation of 75 degrees

C:-A maximum proximal neck diameter of 26 mm

D:-A common iliac artery landing zone length of 25 mm

Correct Answer:- Option-B

Question92:-The Nellix Endo Vascular Aneurysm Sealing (EVAS) system represents a significant shift from traditional stent-grafting by focusing on "sac sealing." What is the primary mechanism by which this system prevents Type II endoleaks?

A:-Use of a hydrophilic coating that promotes rapid endothelialization

B:-Total obliteration of the aneurysm sac using polymer-filled "endobags"

C:-Deployment of multiple fenestrations to maintain branch vessel flow

D:-Implementation of a suprarenal active fixation mechanism with hooks

Correct Answer:- Option-B

Question93:-A 68-year-old diabetic patient with Chronic Limb-Threatening Ischemia (CLTI) and a non-healing heel ulcer undergoes a successful endovascular

revascularization of the posterior tibial artery. Post-procedurally, a ^{99m}Tc-tetrofosmin SPECT/CT perfusion study is performed. According to recent clinical evidence regarding the prognostic value of SPECT/CT in this setting, which of the following is the most significant clinical utility of this modality?

A:-It is the gold standard for identifying the anatomical site of arterial stenosis compared to Digital Subtraction Angiography (DSA).

B:-It provides a more accurate assessment of macrovascular flow than the Ankle-Brachial Index (ABI) in patients with medial arterial calcification

C:-It can quantify regional microvascular perfusion within specific angiosomes to predict 12-month amputation-free survival

D:-It is primarily used to differentiate between atherosclerotic plaque inflammation and medial arterial calcification

Correct Answer:- Option-C

Question94:-62-year-old male presents 48 hours after the sudden onset of coldness and numbness in his left leg. He has a history of a femoropopliteal bypass with a prosthetic graft 2 years ago. Imaging confirms acute prosthetic graft thrombosis (Rutherford Category IIa). Catheter-directed thrombolysis (CDT) is initiated. Which of the following statements regarding the use of pharmacological agents and outcomes in this scenario is most accurate according to current evidence?

A:-Recombinant tissue plasminogen activator (rt-PA) has demonstrated significantly higher limb salvage rates compared to Urokinase in randomized controlled trials (RCTs)

B:-The addition of weight-adjusted systemic Heparin during CDT does not increase the risk of major bleeding but significantly accelerates thrombus resolution

C:-Fibrinogen levels should be monitored every 6–12 hours, and thrombolysis should typically be suspended if levels drop below 100–150 mg/dL

D:-Successful lysis of a prosthetic graft thrombus without an identified underlying structural lesion (e.g., stenosis) carries a 1-year patency rate equivalent to vein grafts

Correct Answer:- Option-C

Question95:-In the context of quality improvement and value-based healthcare, which of the following has been identified as the most common “preventable” cause for 30-day unplanned readmission following major lower extremity bypass surgery?

A:-Acute graft occlusion due to technical error

B:-Surgical site infections (SSI) and wound complications

C:-New-onset myocardial infarction (MI)

D:-Electrolyte imbalances and postoperative ileus

Correct Answer:- Option-B

Question96:-

In light of the recently reported 5-year outcomes from the PARTNER 3 and Evolut Low Risk trials comparing Transcatheter Aortic Valve Implantation (TAVI) to Surgical Aortic Valve Replacement (SAVR) in low-risk patients, which of the following statements regarding long-term clinical outcomes is most accurate?

A:-The initial superiority of TAVI over SAVR in the composite primary endpoint (death, stroke, or rehospitalization) observed at 1 year is sustained throughout the 5-year follow-up period

B:-At 5 years, TAVI is associated with a significantly higher rate of all-cause mortality compared to SAVR, leading to a Grade 1A recommendation against its use in patients under 75

C:-While early benefits in rehospitalization and stroke are attenuated over time, TAVI maintains a significantly lower risk of new-onset atrial fibrillation and life-threatening bleeding compared to SAVR at 5 years

D:-Structural valve deterioration (SVD), defined by hemodynamics, occurs at a significantly higher rate in the TAVI group compared to the SAVR group at the 5-year landmark

Correct Answer:- Option-C

Question97:-A 65-year-old male with a history of atrial fibrillation presents with sudden onset of severe right leg pain and "coldness" for 4 hours. On examination, the limb is pale with minimal sensory loss limited to the toes. He has no motor weakness. Bedside Doppler examination reveals inaudible arterial signals at the pedal level but audible venous signals. According to the Rutherford classification for acute limb ischemia, what is the most appropriate management category and recommended time frame for revascularization?

A:-Category I (Viable); Revascularization can be performed electively within 24-48 hours

B:- Category IIa (Marginally Threatened); Revascularization is urgent and should ideally occur within 6-24 hours

C:-Category IIb (Immediately Threatened); Emergent revascularization is required within 6 hours

D:-Category III (Irreversible); Primary amputation is indicated due to profound nerve damage

Correct Answer:- Option-B

Question98:-A 54-year-old female presents with acute dyspnoea and pleuritic chest pain. Her heart rate is 108 bpm and her systolic blood pressure (SBP) is 105 mmHg. CT Pulmonary Angiography (CTPA) confirms a saddle pulmonary embolus with a right ventricle-to-left ventricle (RV/LV) ratio of 1.2. Her troponin I is elevated. According to the

latest 2024—2026 expert consensus and the clinical framework established by trials like PEITHO-3 and HI-PEITHO, which of the following is the most appropriate management strategy?

A:-Immediate systemic full-dose thrombolysis (100 mg Alteplase) to prevent further hemodynamic collapse

B:- Initiation of therapeutic anticoagulation (e.g., LMWH) and close monitoring for hemodynamic decompensation

C:-Placement of a retrievable Inferior Vena Cava (IVC) filter as first-line therapy to prevent further embolization

D:-Direct transfer for emergency surgical embolectomy due to the presence of a saddle embolus

Correct Answer:- Option-B

Question99:-70-year-old diabetic patient presents with a 2 cm deep ulcer over the first metatarsal head and mild cellulitis. Non-invasive studies reveal an Ankle-Brachial Index (ABI) of 0.45 and a Toe Pressure of 35 mm Hg. According to the Wifl Classification System and the Global Vascular Guidelines (GVG), which of the following best describes this patient's clinical status and the recommended management strategy?

A:-Wifl Stage 1 (Low Risk); Primary wound care and offloading are sufficient, as the ischemia is mild

B:-Wifl Stage 3 or 4 (High Risk); The risk of amputation at 1 year is high, and early revascularization is strongly recommended

C:-Wifl Stage 2 (Moderate Risk); Revascularization is only indicated if the wound fails to heal after 12 weeks of conservative therapy

D:-Wifl Stage 5 (Irreversible); Primary major amputation is the most cost-effective and clinically appropriate intervention

Correct Answer:- Option-B

Question100:-A 22-year-old female presents with a progressive, pulsatile swelling of the right mid-thigh associated with overlying skin warmth and a palpable thrill. MRI/MRA demonstrates a complex network of dilated vessels with early venous filling. According to the ISSVA Classification and the Schobinger Staging System, which of the following is the most appropriate management for this lesion?

A:-Sclerotherapy using 1% Sodium Tetradecyl Sulfate (STS) as the primary definitive treatment

B:-Observation and compression therapy, as these lesions typically involute after the second decade of life

C:-Targeted embolization of the nidus using absolute alcohol or liquid embolic agents (e.g., Onyx), followed by surgical excision if necessary

D:-Proximal ligation of the feeding artery to reduce flow and prevent high-output heart failure

Correct Answer:- Option-C